14th Annual Winter Lung Cancer Conference

Friday-Sunday, February 10-12, 2017, Miami, Florida

Clinical Trials Integrating Immunotherapy and Radiation Therapy

Karen Kelly, MD
Professor of Medicine
Associate Director for Clinical Research
Jennifer Rene Harmon Tegley and Elizabeth Erica Harmon
Endowed Chair in Cancer Clinical Research
UC Davis Comprehensive Cancer Center

Case Presentation

A 59 YO man who presented with DOE. He was found to have right sided pleural effusion. An ultrasound-guided thoracentesis was positive for malignant cells c/w an adenocarcinoma of the lung, EGFR and ALK negative. PET scan showed uptake in the effusion and pleura nodules, nodularity and ipsilateral hilum and mediastinum. He was treated with pemetrexed, carboplatin and bevacizumab and achieved a PR. This was followed by bevacizumab maintenance. He did well for 10 months and then progressed. He complains of mild fatigue and anorexia.

Past Medical History:

- Hypertension
- GERD

Family History: Mother with breast cancer

Social History: Former smoker, quit 3 years ago; 30 pack-year history

Physical Exam: Pleasant male, PS=1 Exam WNL

Case Presentation

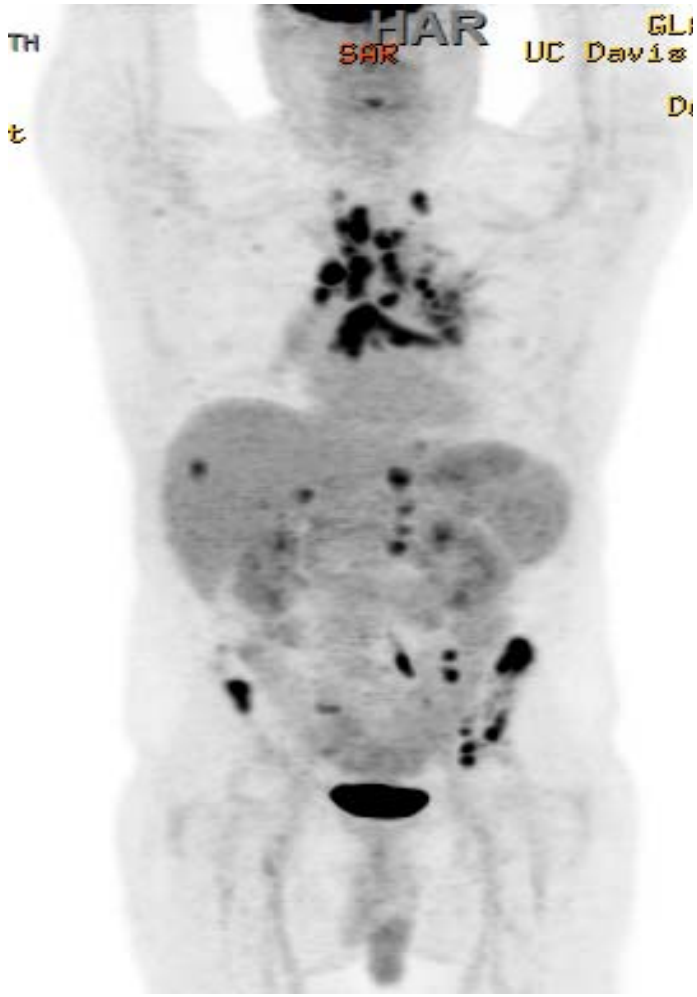

April 2016

SBRT to liver lesion
+
atezolizumab

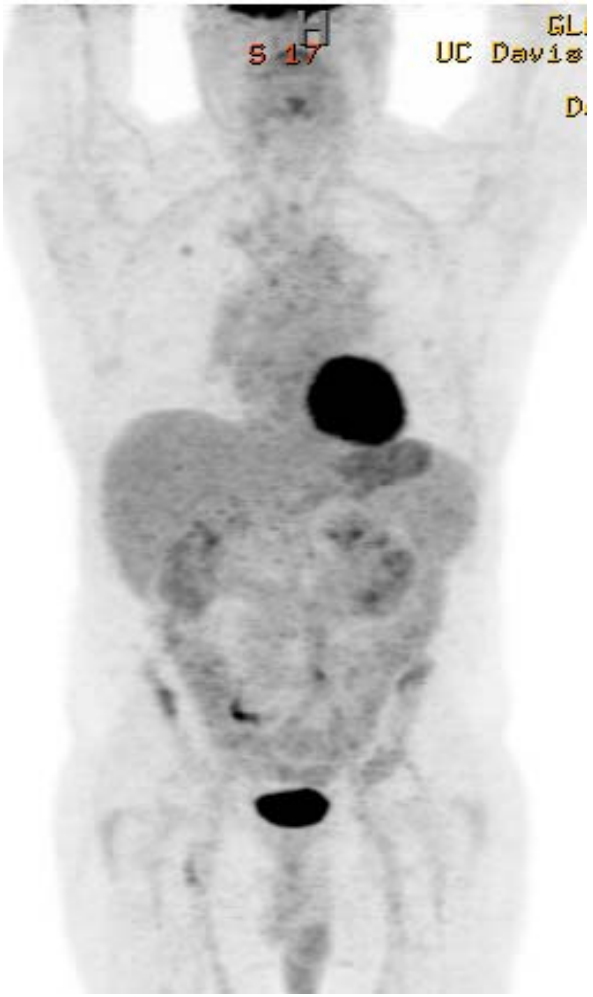

June 2016

14th Annual Winter Lung Cancer Conference

Friday-Sunday, February 10-12, 2017, Miami, Florida

Clinical Trials Integrating Immunotherapy and Radiation Therapy

Karen Kelly, MD
Professor of Medicine
Associate Director for Clinical Research
Jennifer Rene Harmon Tegley and Elizabeth Erica Harmon
Endowed Chair in Cancer Clinical Research
UC Davis Comprehensive Cancer Center

Immunomodulatory Effects of Radiotherapy

- Tumor debulking and releasing tumor antigens
- Not systemically immunosuppressive
- Upregulation of PD-L1
- Upregulation of immunogenic cell surface markers
  - ICAM-1
  - MHC-1
  - Fas
- Secretion of danger signals & cytokines
  - IFN–g
  - TNFa
  - IL-1b
- Induction of immunogenic cell death
  - Calreticulin
  - HMGB-1
- Increased homing of immune cells to tumors
  - Normalization of tumor vasculature
  - Secretion of chemo-attractants (cxcl16)
  - Endothelial expression of VCAM-1
  - Improved T-cell homing to tumors

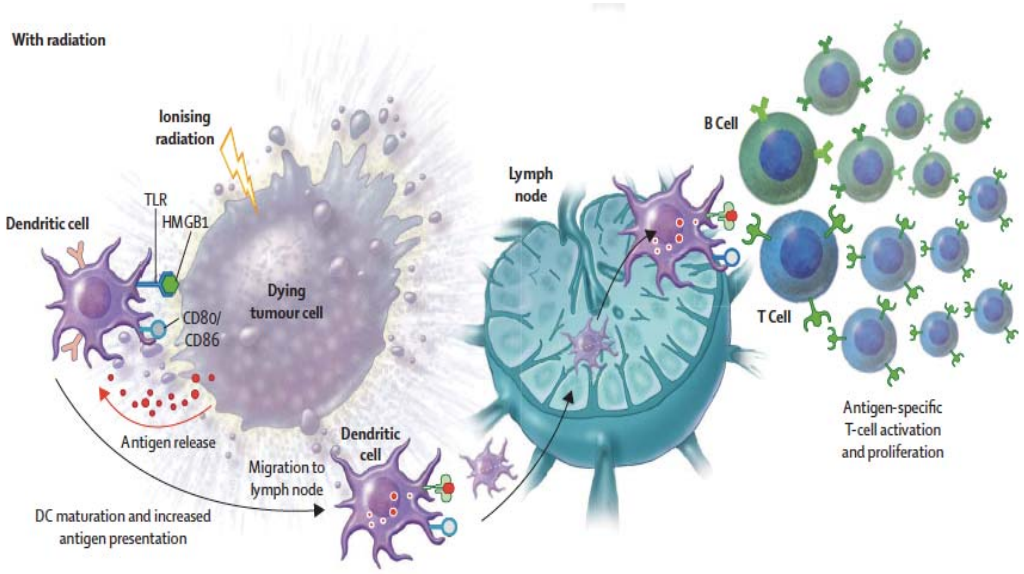

- Improved antigen presentation by APCs
  - Irradiated tumors prime dendritic cells
  - Improved antigen presentation via TLR-4
- Depletion of immunosuppressive cells
- Shifting TAM polarization to M1

Dovedi et al. Cancer Res 2014;19:5458; Chakraborty et al. J Immunol 2003;170:6338; Formenti et al. Lancet Oncol 2009;10:718; Chakraborty et al. J Immunol 2003;170:6338; Lugade et al. J Immunol 2008;180:3132; Obeid et al. Cell Death Differ 2007;14:1848; Apetoh et al. Nature Med 2007;13(9):1050; Ganss et al. Cancer Res 2002;62:1462; Matsumura et al. J Immunol 2008;181:3099; Lugade et al. J Immunol 2008;180:3132; Klug et al. Cancer Cell 2013;24:589-602; Strome et al. Cancer Res 2002;62:1884; Apetoh et al. Nature Med 2007;13(9):1050; Wu et al. Clin Cancer Res 2014;20:644-57; Klug et al. Cancer Cell 2013;24:589-602; Lock M. Cureus 2015.

Preclinical Evidence for Synergy Between Radiation and PD-1 Pathway Inhibitors

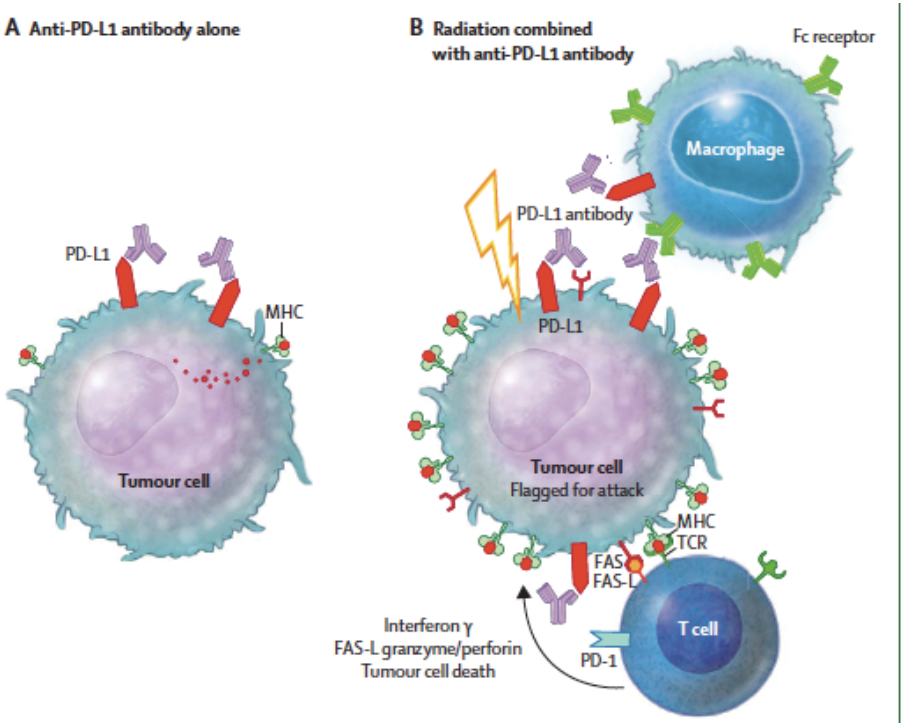

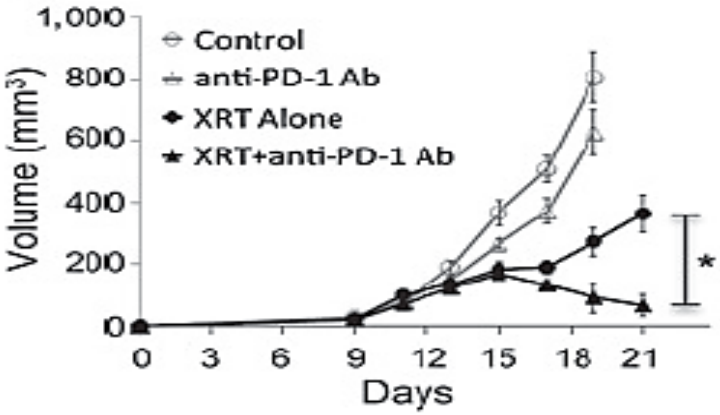

OVA-B16 melanoma model
Anti-PD-1 Ab given 1 day prior to XRT (day 12) q 3 days x 3
*P<0.05

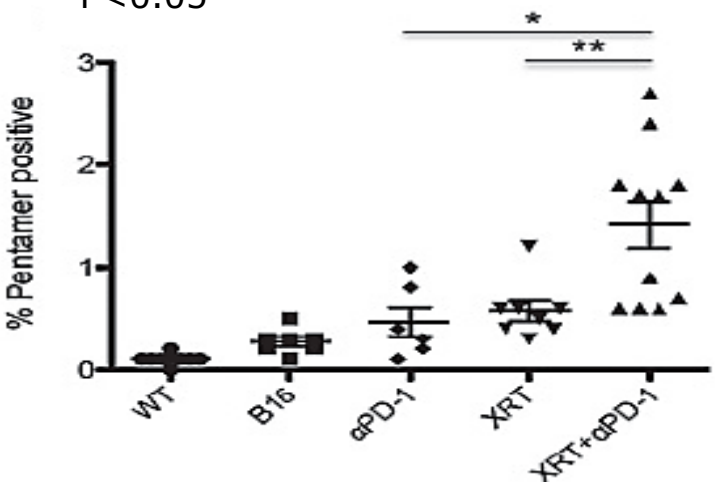

Tumor antigen specific T cells
*P<0.05; **P<0.01

Sharabi AB et al. Lancet Oncol 2015
Sharabi AB et al. Cancer Immunol Res epub Oct 2015

SBRT + Immune Checkpoint Inhibitor

Pre-clinical data suggests that timing of
RT + C.I. is critical to synergy

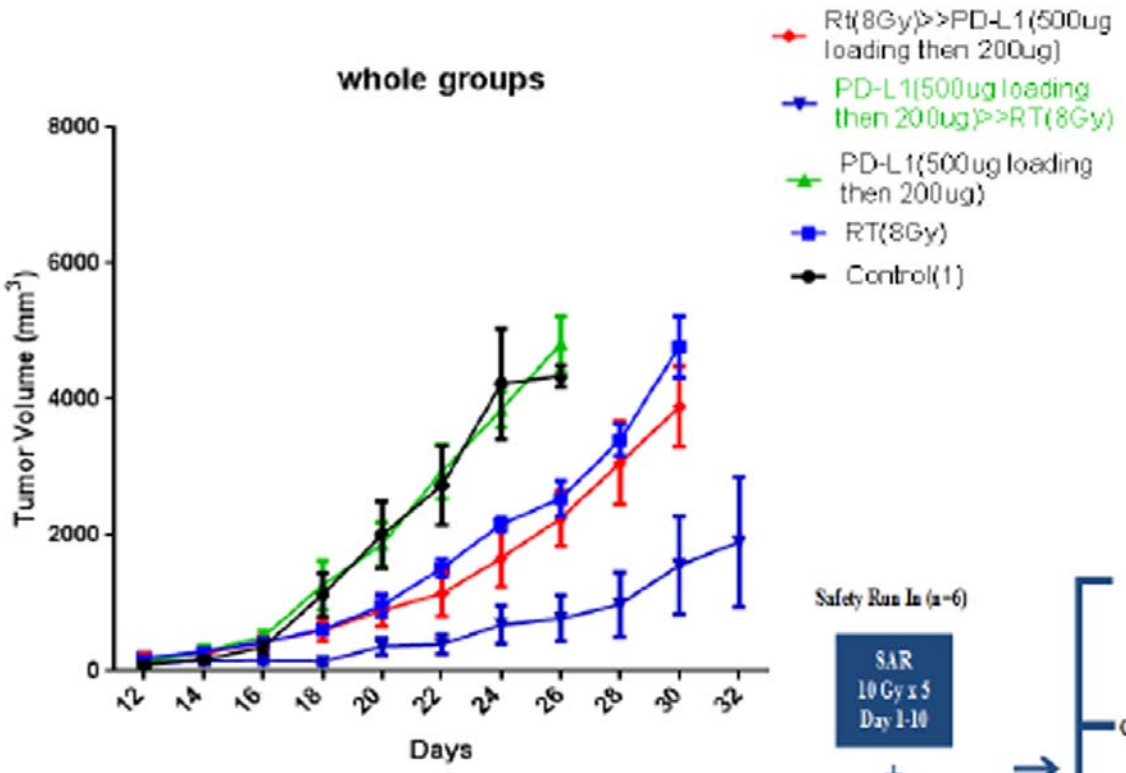

Active Clinical Trial

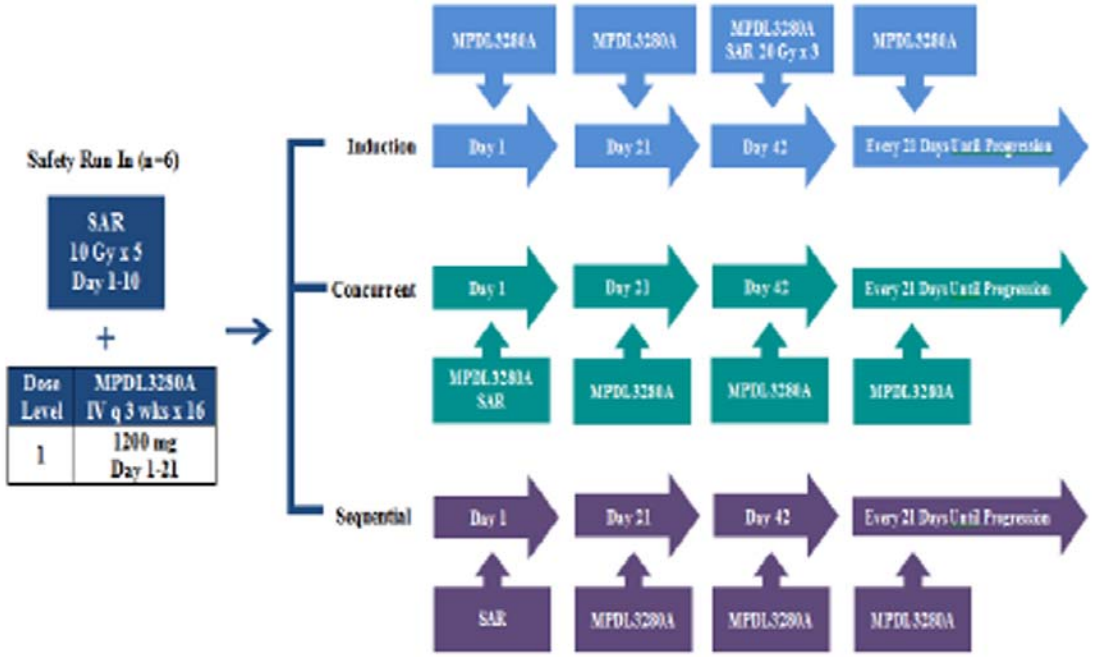

Radiotherapy + Immune Checkpoint Inhibitors Clinical Trials

	Trial Name
1	Atezolizumab and Stereotactic Body Radiation Therapy in Treating Patients With NSCLC
2	MPDL3280A and Stereotactic Ablative Radiotherapy in Patients With Non-small Cell Lung Cancer
3	A Pilot Study of MPDL3280A and HIGRT in Metastatic NSCLC
4	Hypofractionated Radiation Therapy to Improve Immunotherapy Response in Non-Small Cell Lung Cancer
5	MK-3475 and Hypofractionated Stereotactic Radiation Therapy in Patients with NSCLC
6	Pembrolizumab and Stereotactic Radiosurgery for Melanoma or NSCLC Metastases
7	Hypofractionated Radiation Therapy to Improve Immunotherapy Response in Non-Small Cell Lung Cancer
8	Neoadjuvant Chemoradiation Plus Pembrolizumab Followed By Consolidation Pembrolizumab in NSCLC
9	A Randomized Two Arm Phase II Trial of Pembrolizumab Alone or Sequentially Following Single Fraction Non-ablative Radiation to One of the Target Lesions, in Previously Treated Patients With Stage IV NSCLC
10	Hypofractionated Radiation Therapy to Improve Immunotherapy Response in Non-Small Cell Lung Cancer
11	Trial of Nivolumab With Radiation or Nivolumab and Ipilimumab With Radiation for the Treatment of Intracranial Metastases From Non-Small Cell Lung Cancer
12	Combining Radiosurgery and Nivolumab in the Treatment of Brain Metastases

Novel Combinations with Radiation and Immunotherapy

Radiotherapy + Intralesional Interleukin-2

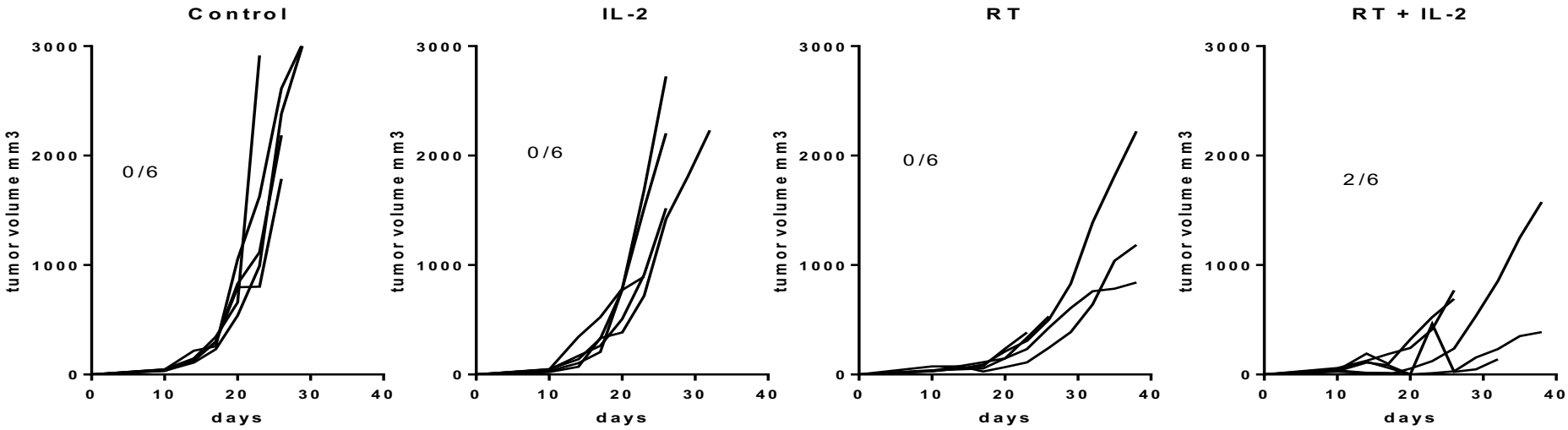

Monjazeb A. Personal communication

Clinical Trial: XRT + Intralesional IL-2 + CI

- IL-2 can upregulate PD-1 expression and activate T-cells. There is data supporting combination therapies with IL-2 and checkpoint blockade, IL-2 and radiotherapy, and checkpoint blockade and radiotherapy.
- We hypothesize that a novel strategy combining radiotherapy and intralesional interleukin-2 (IL-2), may overcome resistance to checkpoint blockade therapy.

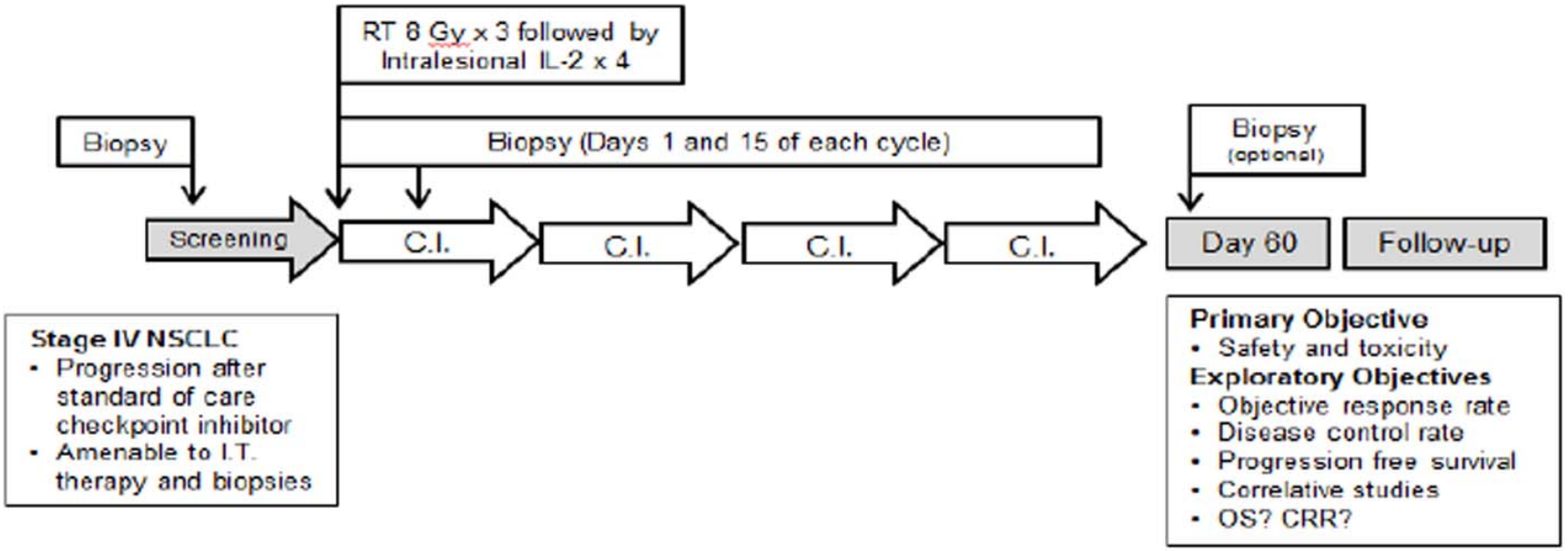

Abbreviations: C.I. = checkpoint inhibitor; CRR = complete response rate; I.T. = intratumoral; OS = overall survival; RT = radiation therapy; NSCLC = non-small cell lung cancer

C.I.: Nivolumab Q2 weeks (one cycle) or pembrolizumab Q3 weeks (one cycle) until intolerable toxicity.
Radiation: 3 fraction of 8 Gy after radiation, 12-96 hours apart with cycle 1 of C.I.
Intralesional IL-2: Four injections biweekly (2 injections per week, for 2 weeks, each injection ≥48 hours apart), starting 24-72 hours after completion of radiotherapy.
Biopsy: Patients undergo biopsies at screening, Days 1 and 15 of each cycle, and optionally at Day 60.
Follow-up: Patients will remain on protocol treatment until progression or completion of 6 months of treatment. Patients will be followed with CT chest, labs, and clinic visit every 60 days.

Novel Combinations with Radiation and Immunotherapy

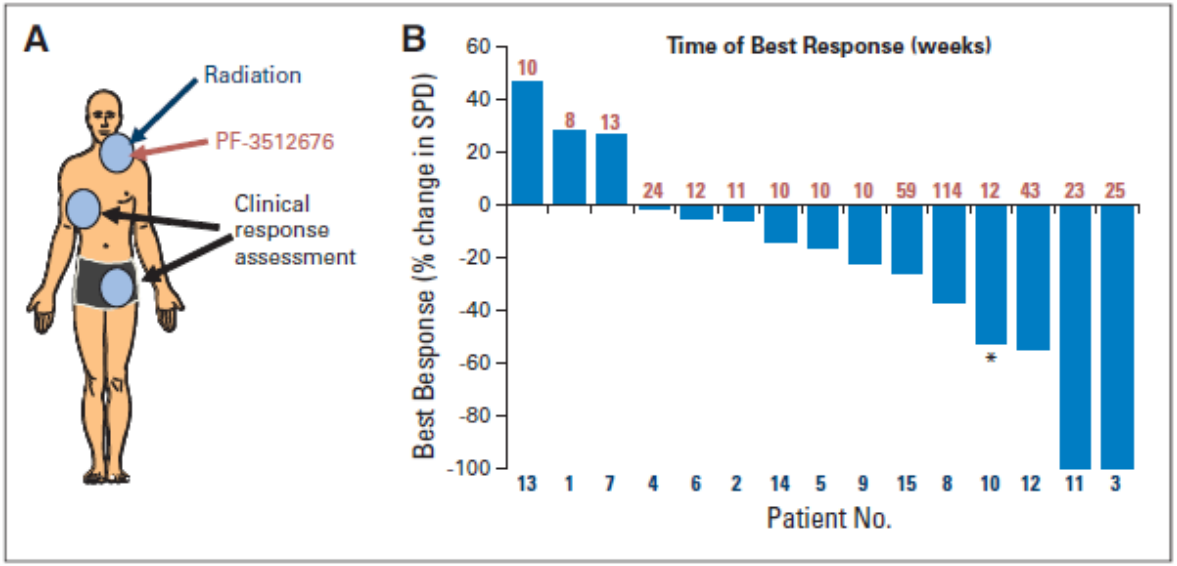

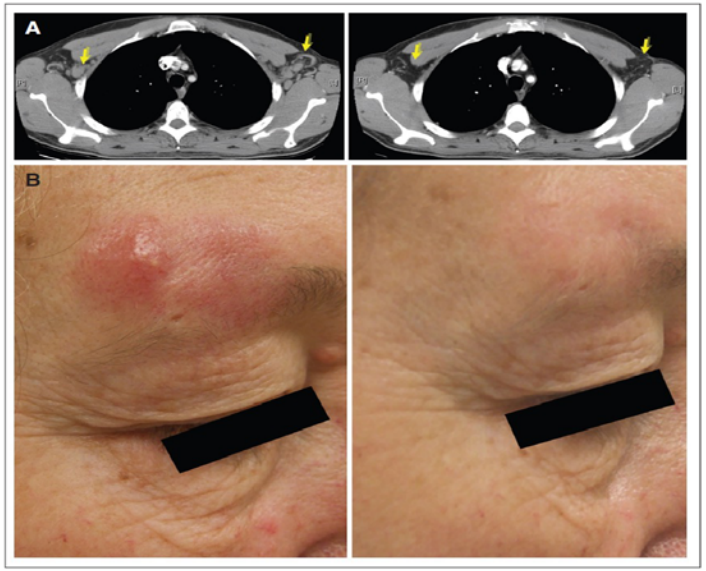

Two clinical trials from Stanford demonstrate the efficacy of combining RT + CpG: 27% abscopal response rate

Brody JD et al. J Clin Oncol 2010

Patients Whose Tumors Induce Tregs Are Less Likely To Respond To Therapy

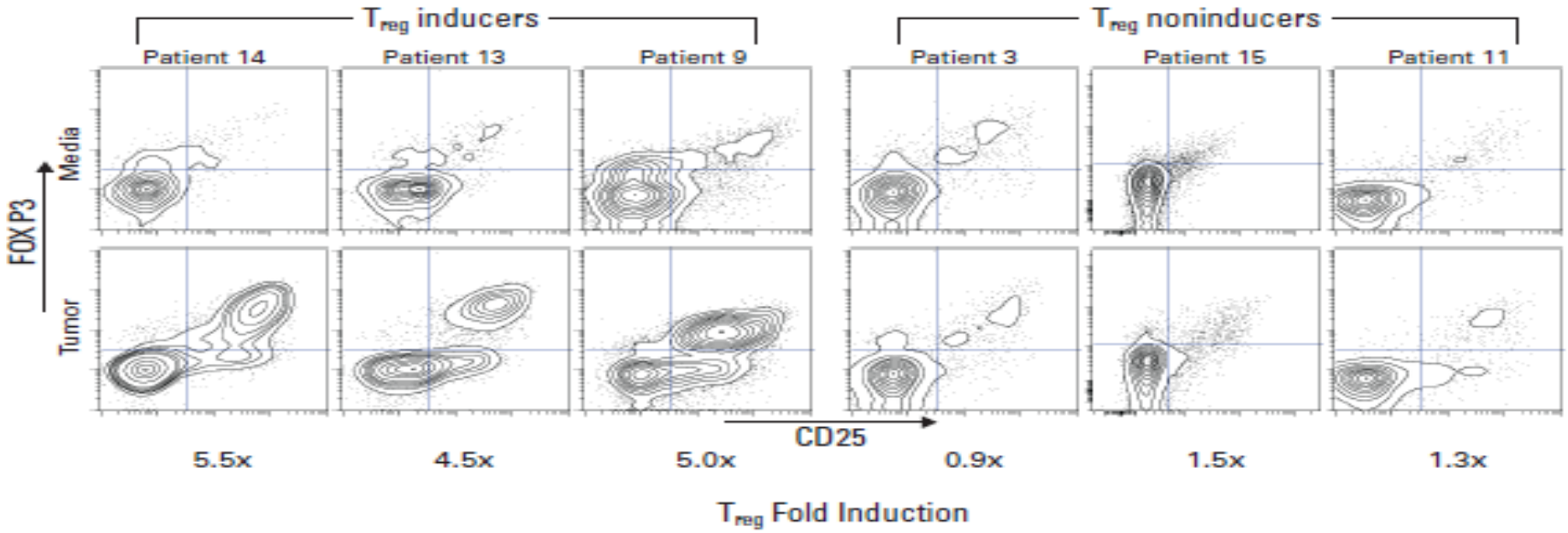

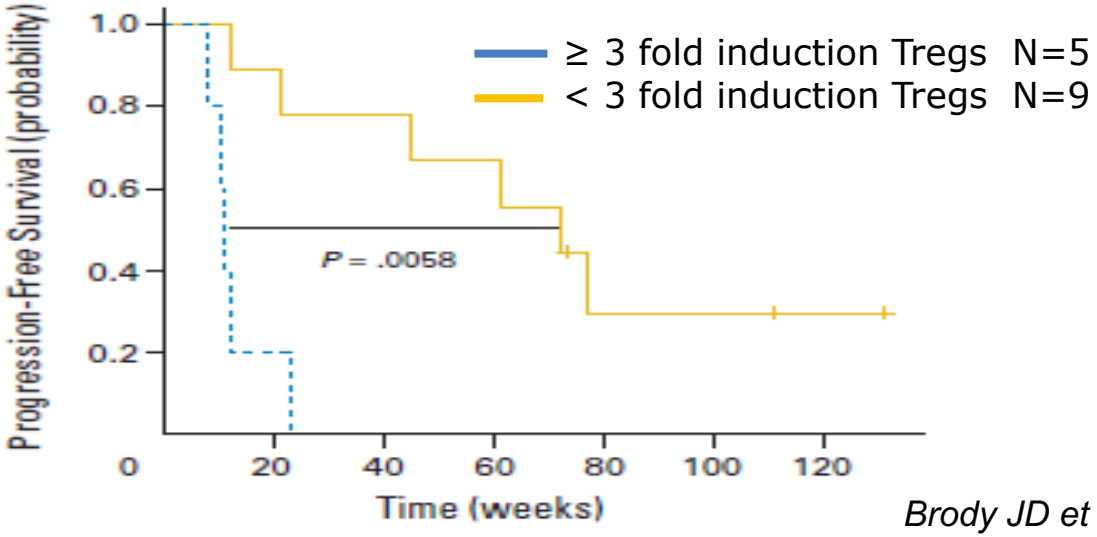

Brody JD et al. J Clin Oncol 2010

Hypothesis: IDO upregulation after immunostimulatory therapies (XRT + CpG) maintains tumor microenvironment immune suppression and limits treatment efficacy that can be overcome with the addition of an IDO inhibitor

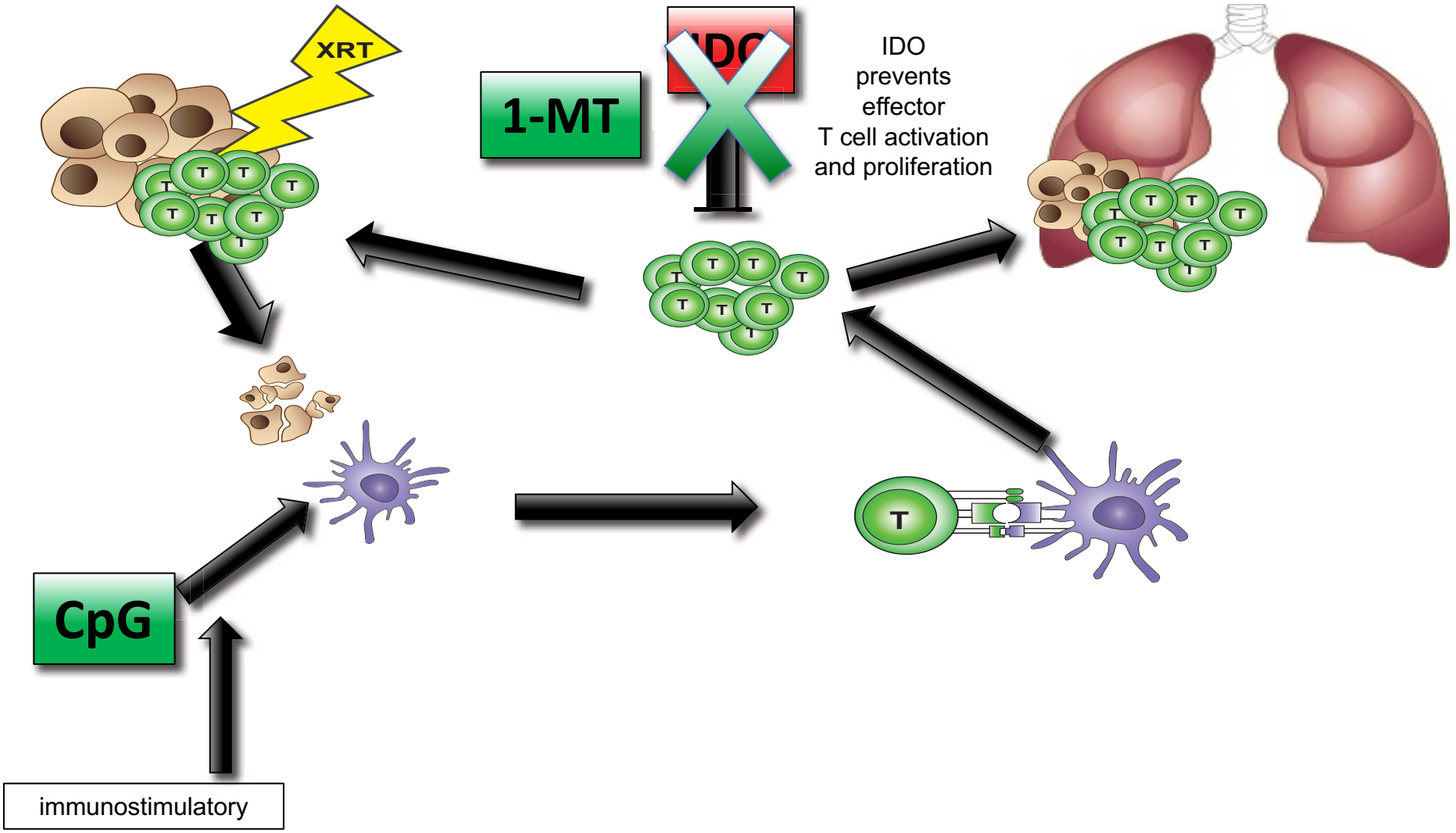

IDO Expression Is Upregulated By Inflammatory Therapies

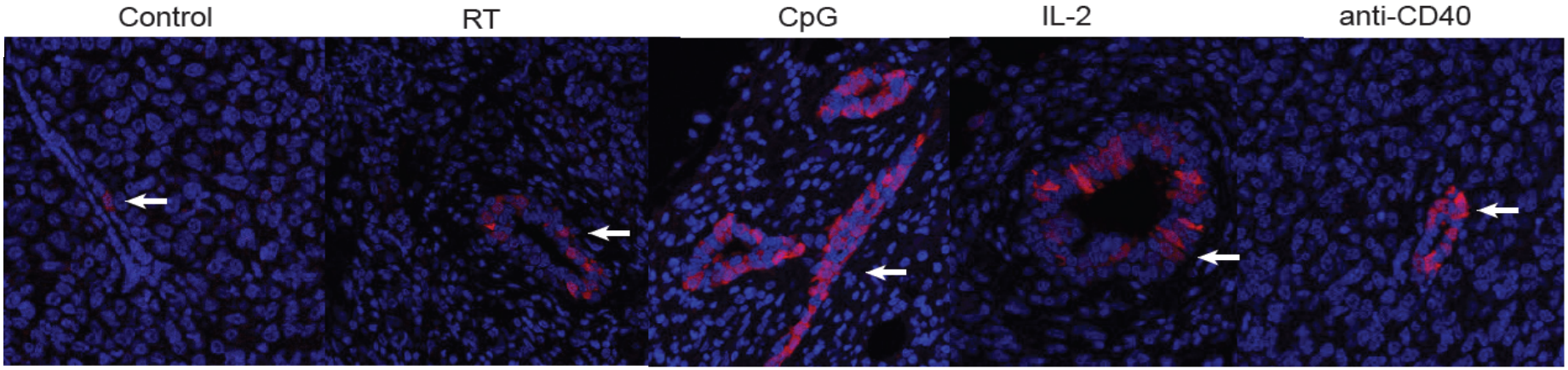

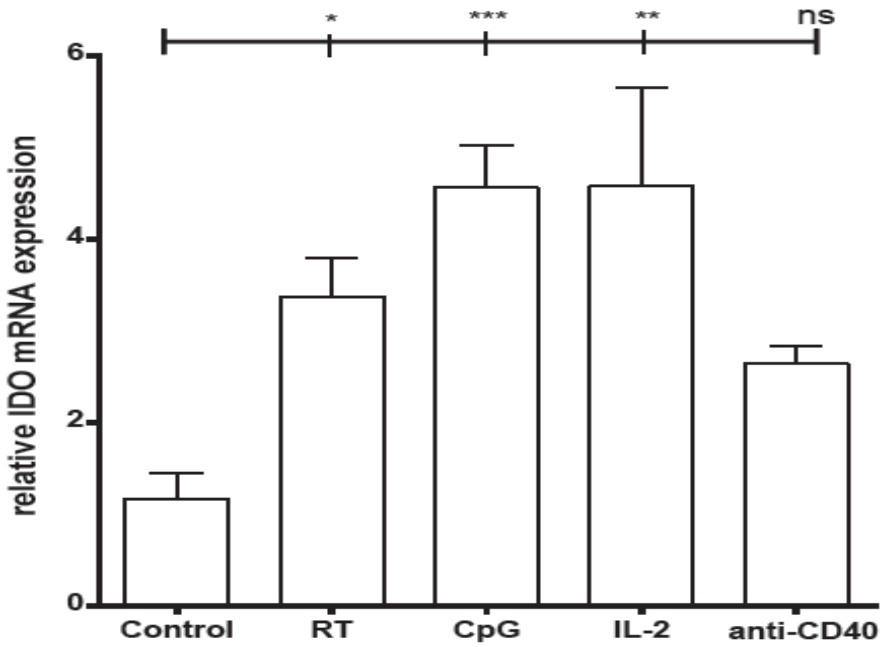

Monjazeb AJ et al. Clin Cancer Res 2016

IDO Blockade Improves Anti-tumor Effects of RT + CpG

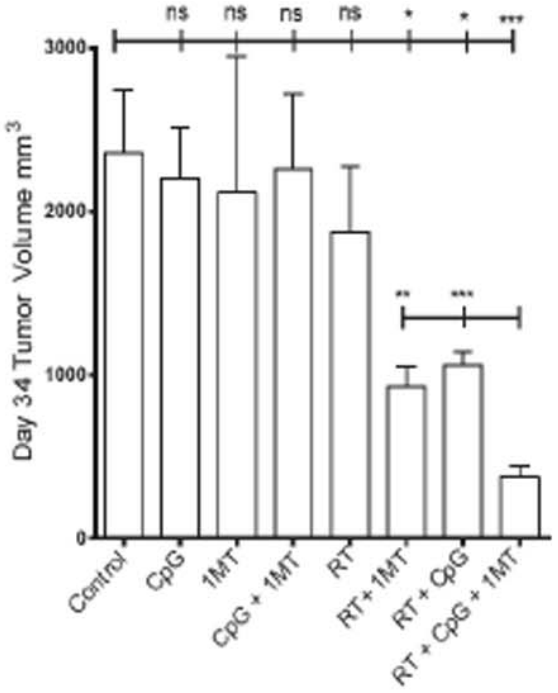

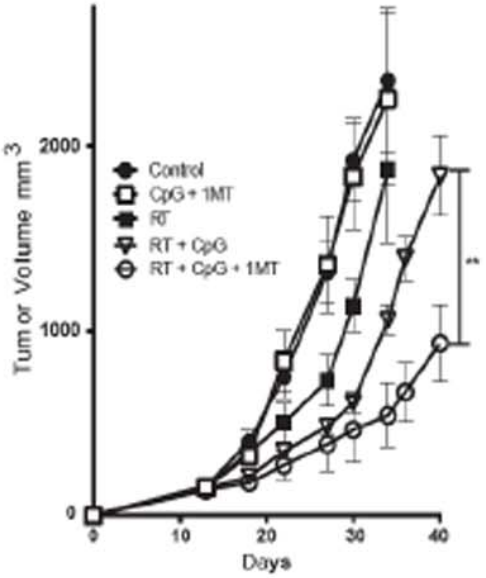

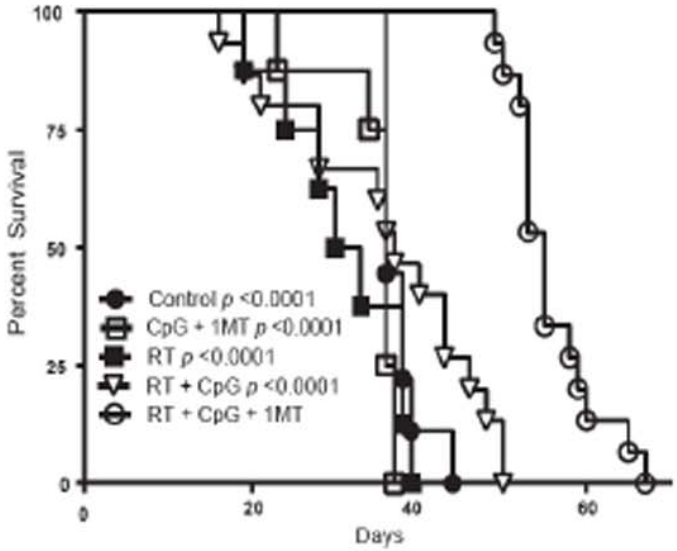

Triple Therapy Eliminates Systemic Disease

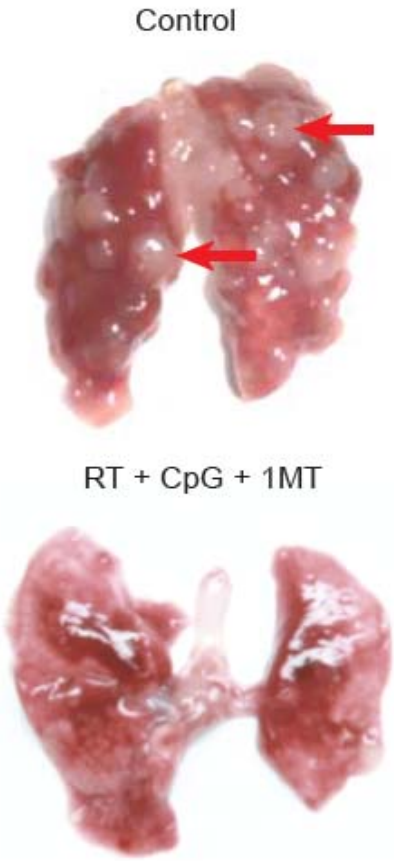

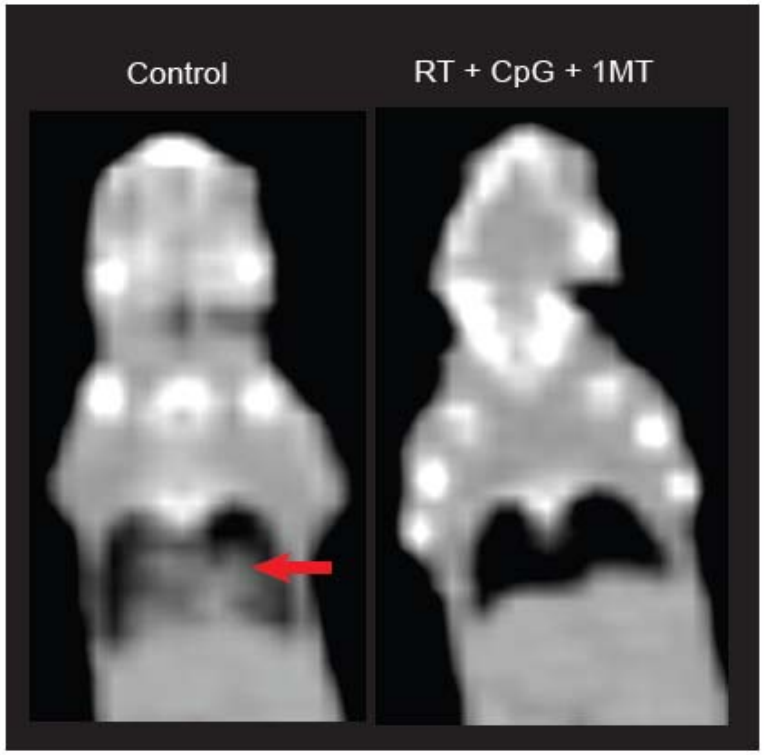

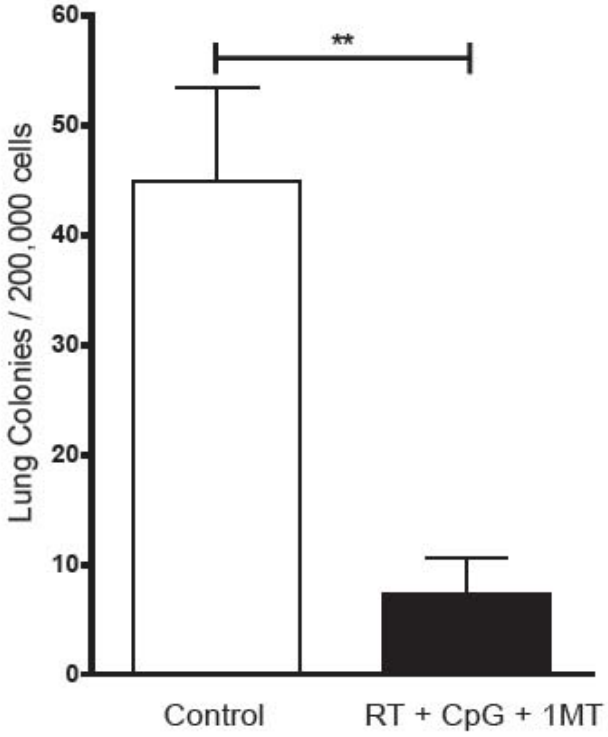

Mechanism: Reduction of Tregs

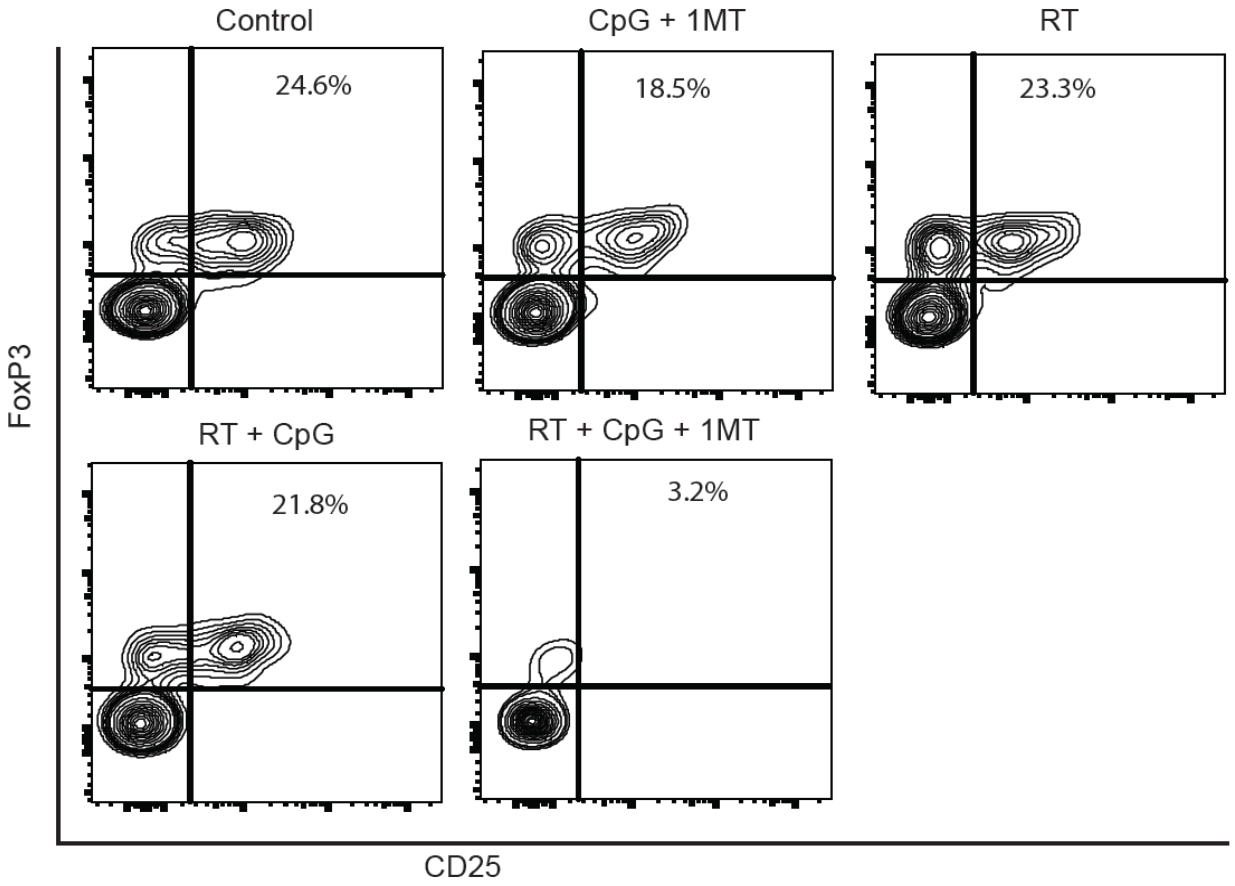

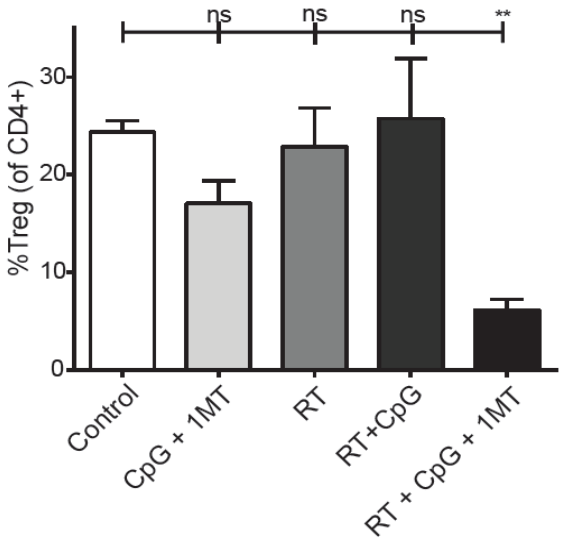

Canine Trial: Study Design

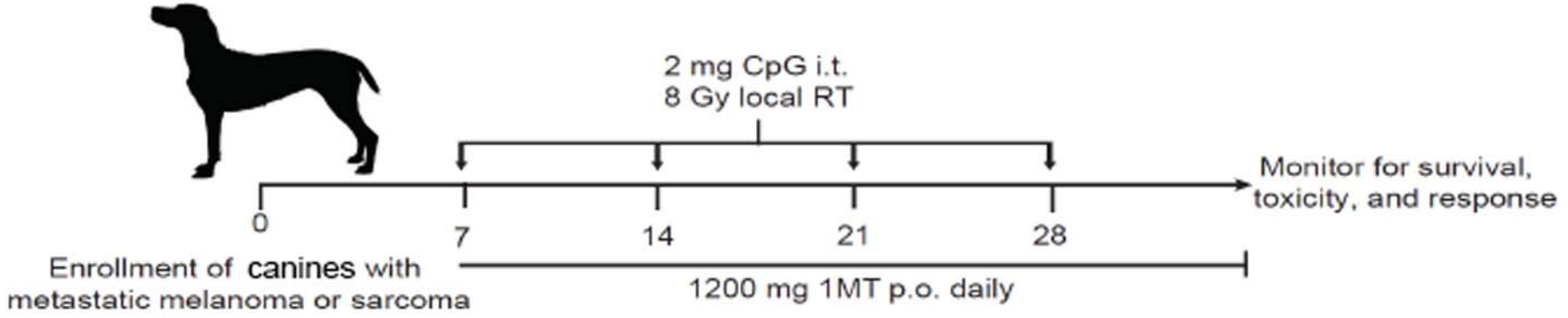

Response at the primary site

Abscopal response

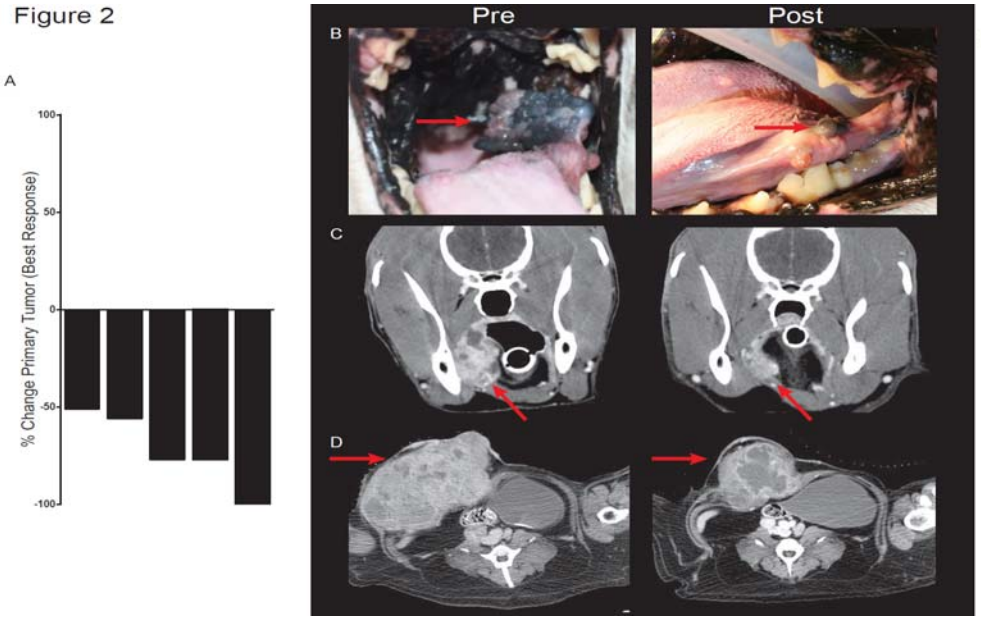

Monjazeb AJ et al. Clin Cancer Res 2016

Mechanism: Reduction of Tregs

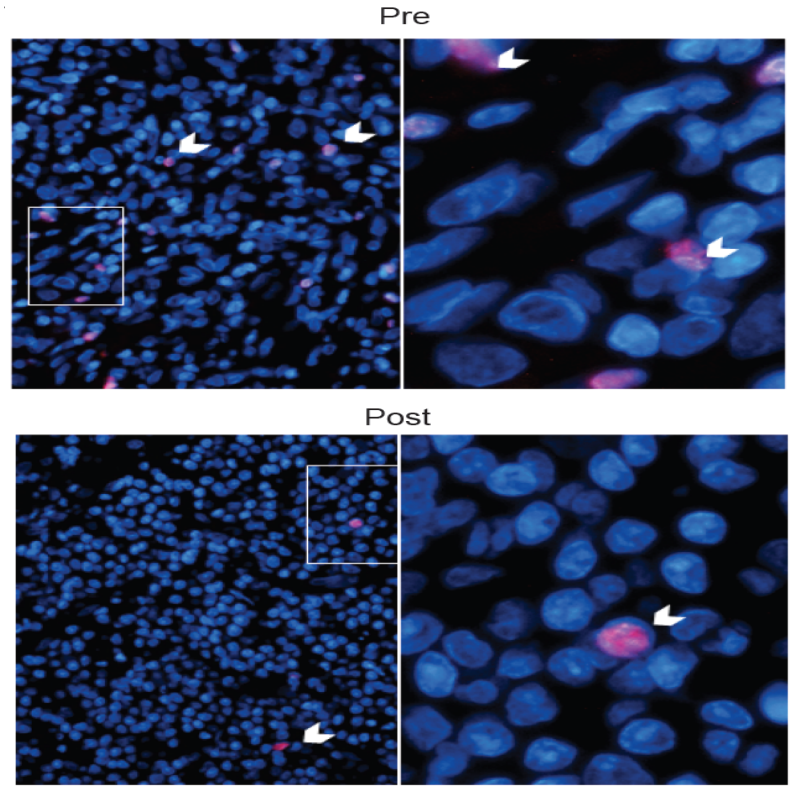

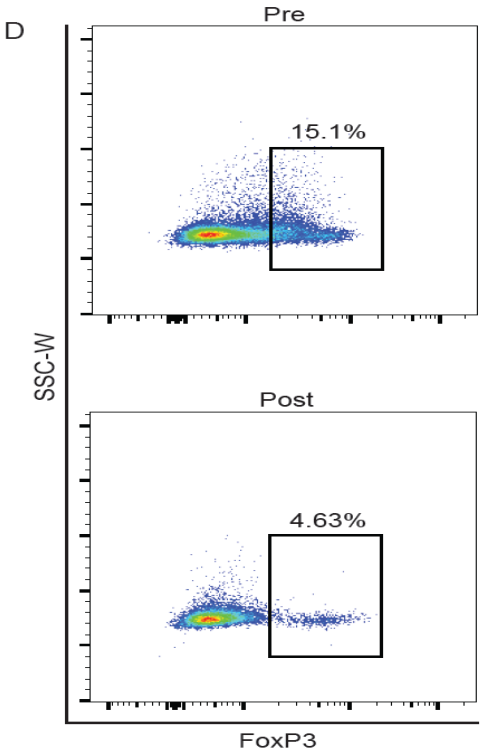

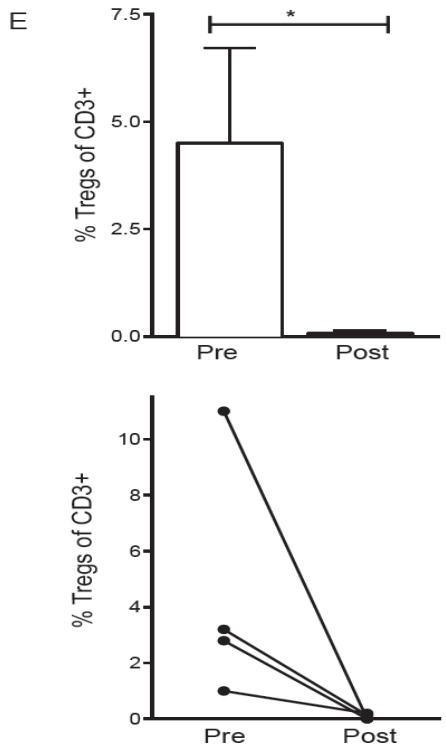

FoxP3 staining

Increase in CD8 T cells post treatment (not shown)

Human Clinical Trial

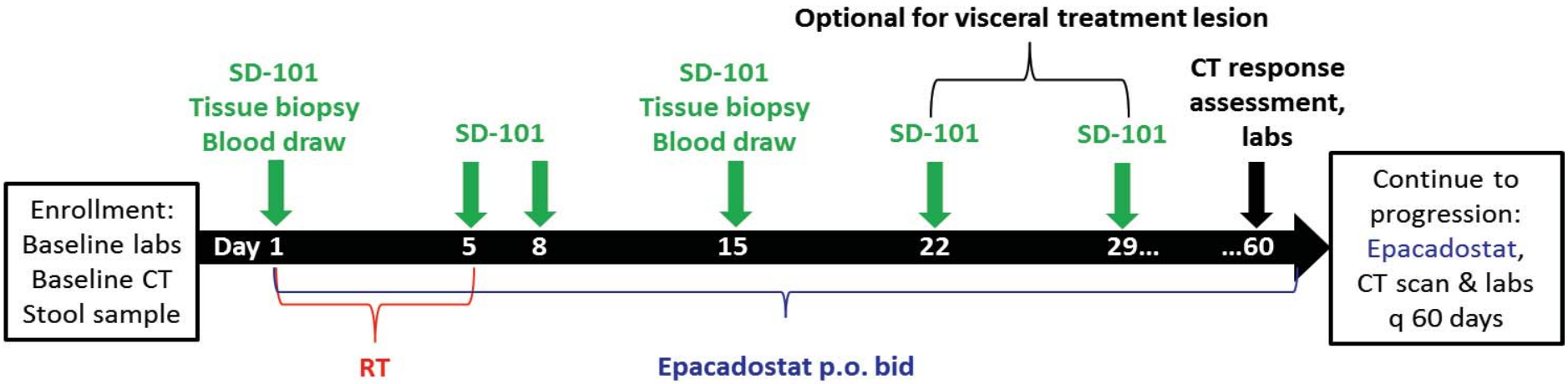

Concurrent RT (day 1-5)
Cohort 1 (solid tumors and high-grade lymphoma): (8Gy x 3) or (4Gy x 5)
Cohort 2 (low-grade lymphoma): (2Gy x 2)
+
Intralesional SD-101 (Day 1,5,8,15,22,29)
4mg injection into RT treatment lesion
+
Epacadostat
100-300 mg p.o. bid

Summary

- The therapeutic effect of radiation therapy is influenced by the immune response that is elicited.

- Preclinical evidence supports the clinical evaluation of radiation plus immunotherapy combinations.

- Key questions to address are:
  a) the optimal sequence of the combination
  b) radiation dose, schedule and target site
  c) biomarkers of response and resistance